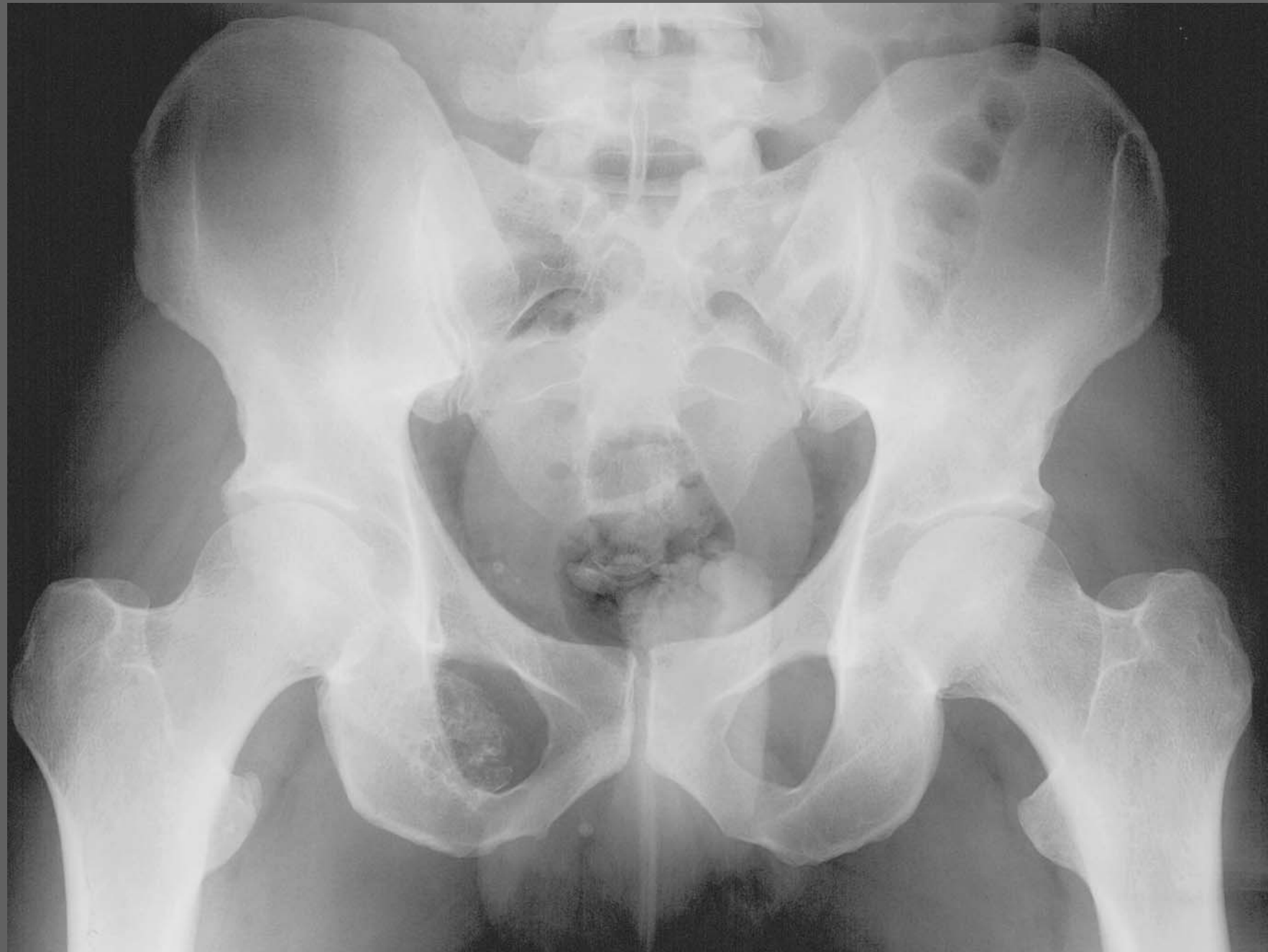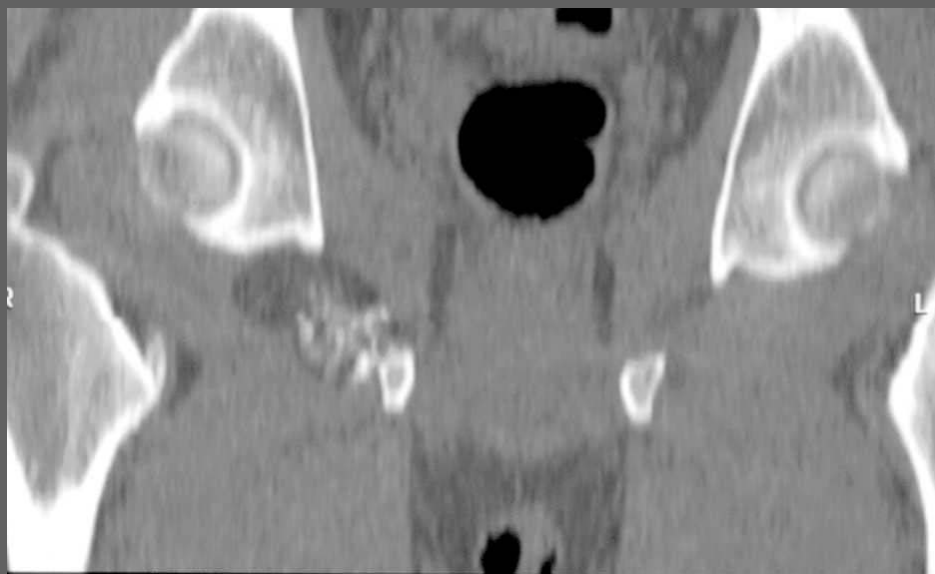
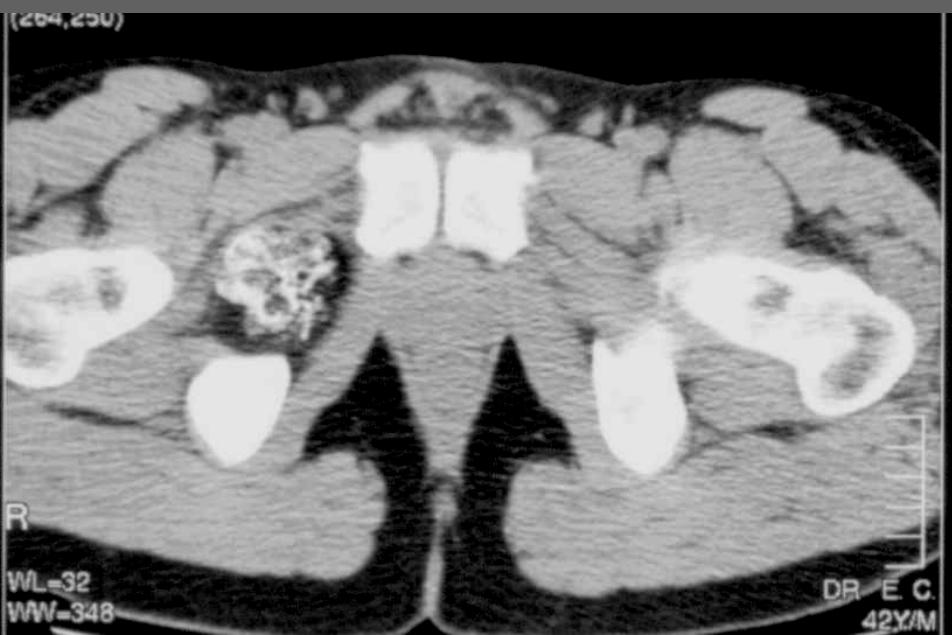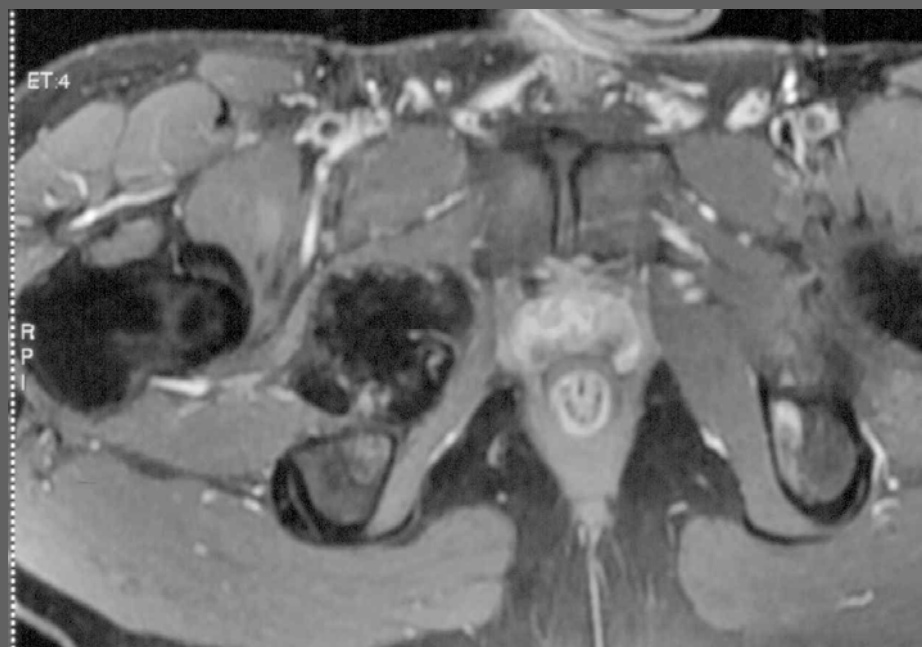


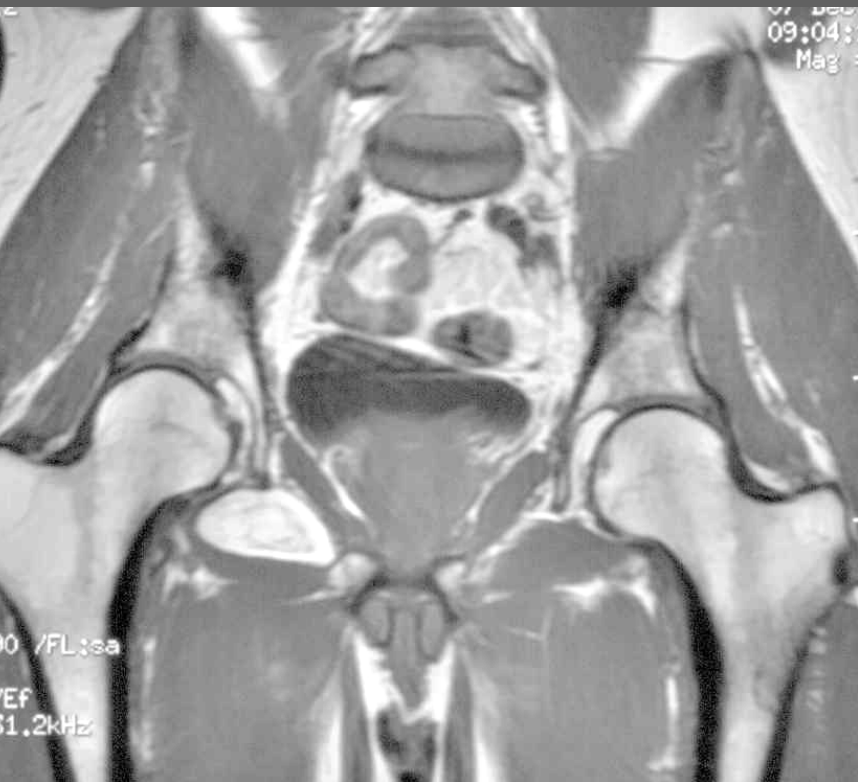# Cas clinique n° 3

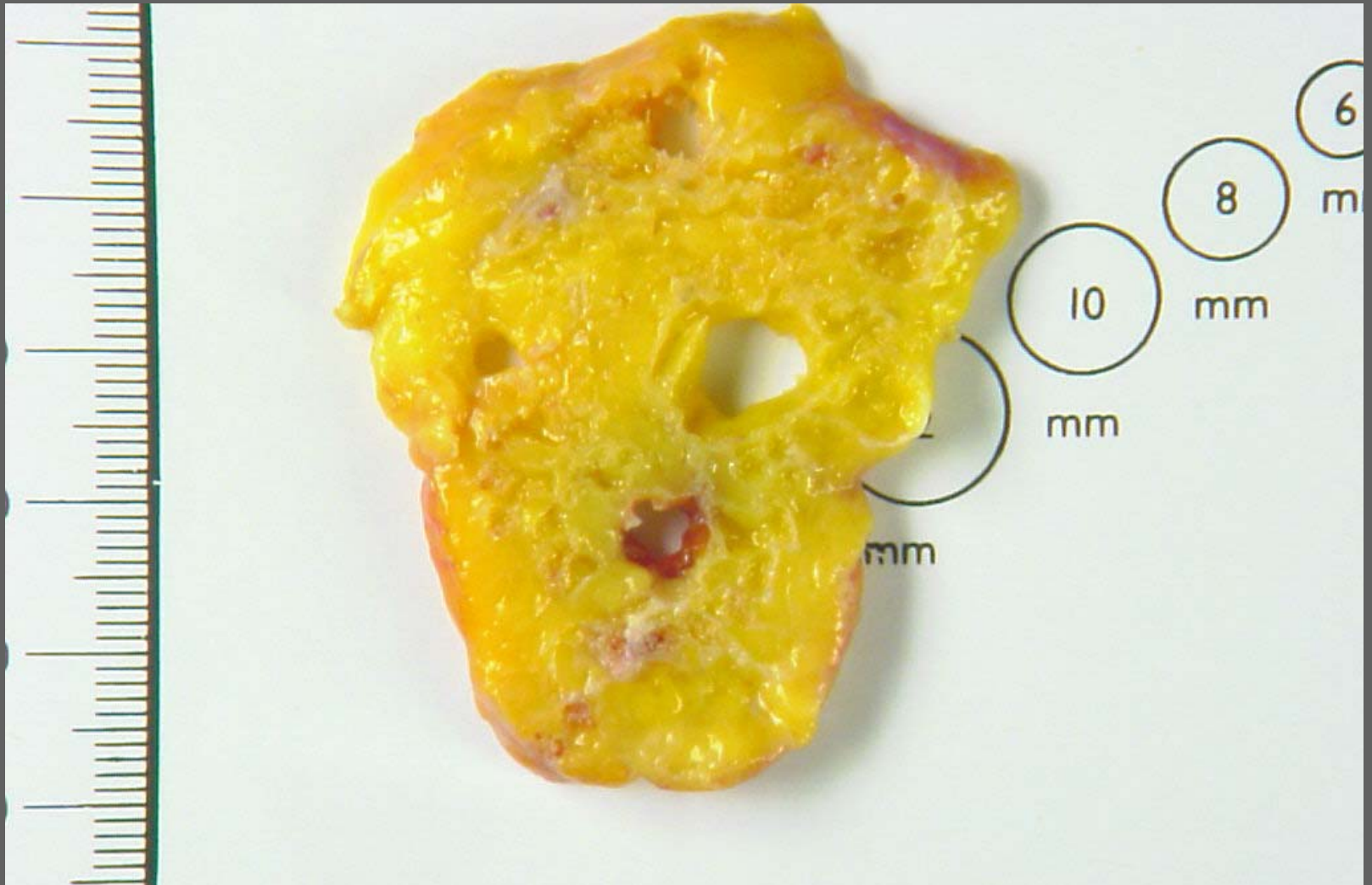- Homme de 42 ans
- Accident de la voie publique
- Radiographie systématique







# Cas # 3



# Cas # 3

